


# MEDICATION-RELATED OSTEONECROSIS OF THE JAW IN CANCER PATIENTS: CASE SERIES AND REVIEW OF THE CURRENT LITERATURE

OSTEONECROSIS DE LA MANDÍBULA RELACIONADA CON MEDICAMENTOS EN PACIENTES CON CÁNCER: SERIE DE CASOS Y REVISIÓN DE LA LITERATURA ACTUAL

**Karen Maciel Reyes Castillo**<sup>1\*</sup>   
kren\_93\_14@hotmail.com

**Miguel Ángel Ocampo Benítez**<sup>2</sup>   
maxilocampo@outlook.com

**Omar Peña Curriel**<sup>3</sup>   
omar.oncologia@outlook.com

## ABSTRACT

Currently, a large proportion of cancer patients are treated with bone modifying agents (BMA). In this regard, the increase in the prescription of these drugs has led to concerns in the increment of osteonecrosis of the jaws. This article describes four patients with BMA cancer treatments requested dental evaluation at our institution due to pain and swelling of the mandibular bone after tooth extraction, tooth loss, or unknown risk factor. Oral and radiographic evaluation reveals Medication-related osteonecrosis of the jaw (MRONJ) at different clinical stages according to the American Association of Oral and Maxillofacial Surgeons (AAOMS) classification. Some patients underwent abscess drainage, oral cleaning and antibiotic therapy with complete recovery. Follow-up showed treatment success in all patients. That is why we emphasize the importance of early establishment of appropriate treatment and emphasize the avoidance of dental procedures during BMA therapy.

**Keywords:** medication-related osteonecrosis, bone-modifying agents, zoledronic acid, denosumab, bevacizumab

## RESUMEN

En la actualidad, una gran cantidad de pacientes con cáncer son tratados con agentes modificadores óseos (AMO). En relación con esto, el aumento en la prescripción de estos fármacos ha generado preocupación por el incremento en la osteonecrosis de los maxilares. Este artículo describe cuatro casos de pacientes con cáncer, tratados con AMO, que acuden a nuestra institución debido a que padecen dolor e inflamación de la mandíbula, después de la extracción dental, así como pérdida de dientes con un factor de riesgo desconocido. La evaluación clínica y radiográfica evidenció osteonecrosis de los maxilares en diferentes etapas clínicas, según la clasificación de la Asociación Estadounidense de Cirujanos Orales y Maxilofaciales (AAOMS). Algunos de los pacientes fueron sometidos a drenaje de abscesos, limpieza bucal y antibioticoterapia con recuperación completa. El seguimiento clínico fue exitoso en todos los pacientes. Es por eso que hacemos énfasis en la importancia de establecer un tratamiento apropiado y evitar procedimientos dentales durante la terapia con AMO.

**Palabras clave:** osteonecrosis relacionada con medicamentos, agentes modificadores óseos, ácido zoledrónico, denosumab, bevacizumab

**Artículo recibido: 23/06/2022**  
**Arbitrado por pares**  
**Artículo aceptado: 13/09/2022**  
**Artículo publicado: 29/09/2022**

\* **Corresponding Author:**  
Karen Maciel Reyes Castillo  
kren\_93\_14@hotmail.com



©Los autores, 2022. Publicado por la Universidad Científica del Sur (Lima, Perú)

**Citar como:** Reyes KM, Ocampo MA, Peña O. Medication-related osteonecrosis of the jaw in cancer patients: case series and review of the current literature. Rev Cient Odontol. Rev Cient Odontol (Lima). 2022; 10(3): e123.  
DOI: 10.21142/2523-2754-1003-2022-123

<sup>1</sup> Universidad Nacional Autónoma de México. Coyoacán, México.

<sup>2</sup> Centro Médico Nacional 20 de Noviembre del ISSSTE. Ciudad de México.

<sup>3</sup> Centro de Cáncer de Mama TecSalud. Nuevo León, México.

## INTRODUCTION

Cancer is one of the major health problems in the world. In 2020, more than 19 million new cases and almost 10 million deaths were reported globally (1). Cancer survivorship has shown a continuous increment in the past decade (2). This increase in patient survival has made the clinicians aware of the prevalence of late and chronic cancer treatment complications. These complications usually appear secondary to the development of distant organ metastases or as a consequence of the drug-related toxicity caused by chronic pharmacologic exposure.

With increasing survival of cancer patients, a large proportion of this population will eventually develop metastatic bone disease and will often suffer skeletal-related events (SREs) such as pain, hypercalcemia, or pathologic fractures (3). For the treatment of metastatic bone disease, bone-modifying agents (BMA) are usually indicated such as denosumab, a monoclonal antibody directed against RANK ligand (RANKL), or bisphosphonates (e. g. zoledronic acid, alendronate), a group of drugs that inhibit the maturation and recruitment of osteoclasts via suppression of the mevalonate pathway. Both drugs have been shown to be useful in decreasing SREs due to metastatic bone disease (4). Likewise, in some patients with advanced cancer, the combination of bevacizumab, a monoclonal antibody directed against vascular-endothelial growth factor, with chemotherapy has been shown to be useful for increasing progression-free survival, in some cancer types (5). In this regard, the augmented prescription of these drugs has led to concerns in the increment in drug-related toxicity such as medication-related osteonecrosis of the jaw (MRONJ).

According to the American Association of Oral and Maxillofacial Surgeons (AAOMS), a case of MRONJ is defined as an exposed bone in the maxillofacial region that has persisted for more than 8 weeks in a patient with previous or current treatment with a BMA or an antiangiogenic agent, without a history of radiotherapy to the head-and-neck region or mandibular bone metastatic disease. In addition, the AAOMS has established management strategies according to the MRONJ stage ranging from conservative treatment in

early stages to surgical debridement and reconstruction for advanced stages (6).

In this article we present, a case-series of four patients with MRONJ in different clinical stages according to the AAOMS classification. Likewise, we review the clinical risk factors associated with each event and delineate the diagnostic and therapeutic approach to the patient with suspected MRONJ. The present article aspires to give practical recommendations for the general practice dentist.

## CASES DESCRIPTION

The patients gave their authorization for the reporting of some of their records and the work complied with the ethical standards of Helsinki.

**Case 1** – A woman with lung cancer treated with antiangiogenic and antiresorptive agents.

A 70-year-old woman diagnosed with advanced non-small cell lung cancer with multiple bone, lung and tumor left adrenal gland metastases. The patient received cytotoxic treatment with carboplatin, pemetrexed and bevacizumab for one year, followed by denosumab for the last three months of follow-up. After the third administration of denosumab, the patient reported dental extraction of the left mandibular second molar and right mandibular first molar was performed outside of our institution. One month later, the patient began with severe pain in the manipulated area, delayed dental healing and paresthesia on the right-side of the mandible.

Table 1. MRONJ preventive measures according to AAOMS

|    |  |
|----|--|
| 1. | Thorough examination of the oral cavity.   |
| 2. | Radiologic evaluation (as needed).   |
| 3. | Identify acute infection sites and potential infections sites and treat accordingly. |
| 4. | Education and motivation of the patient regarding optimal oral hygiene.              |

Adapted from: Ruggiero et al. (6) J Oral Maxillofac Surg 2014; 72:1938-1956

Intraoral examination showed exposure of necrotic bone and purulent secretion with inflammation of the surrounding molar area. Imaging studies showed an osteolytic lesion with changes in the bone trabecular pattern, extending from the mandibular body to the right ascending ramus (Figure 1). Based on these clinical characteristics, we classified the lesion as an AAOMS stage 3.

Treatment for three months with clindamycin was indicated together with mouth rinses with 0.12% chlorhexidine antiseptic solution. The infectious process,

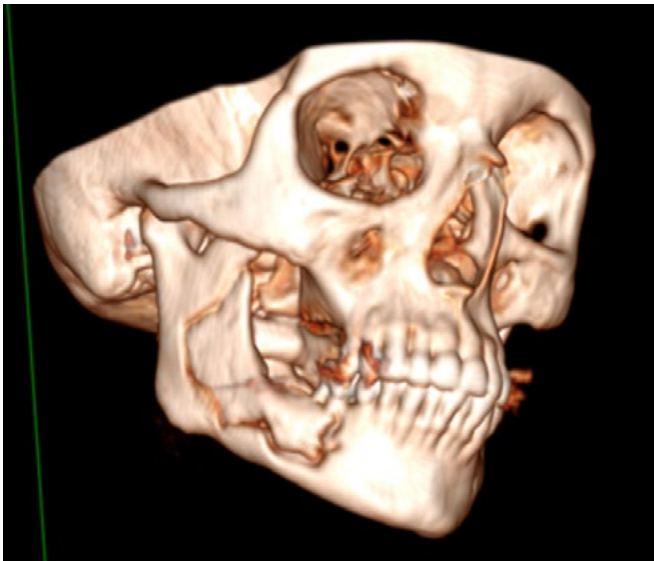
pain and the necrosis extension were successfully resolved.

**Case 2** – A man with multiple myeloma treated with zoledronic acid and prednisone.

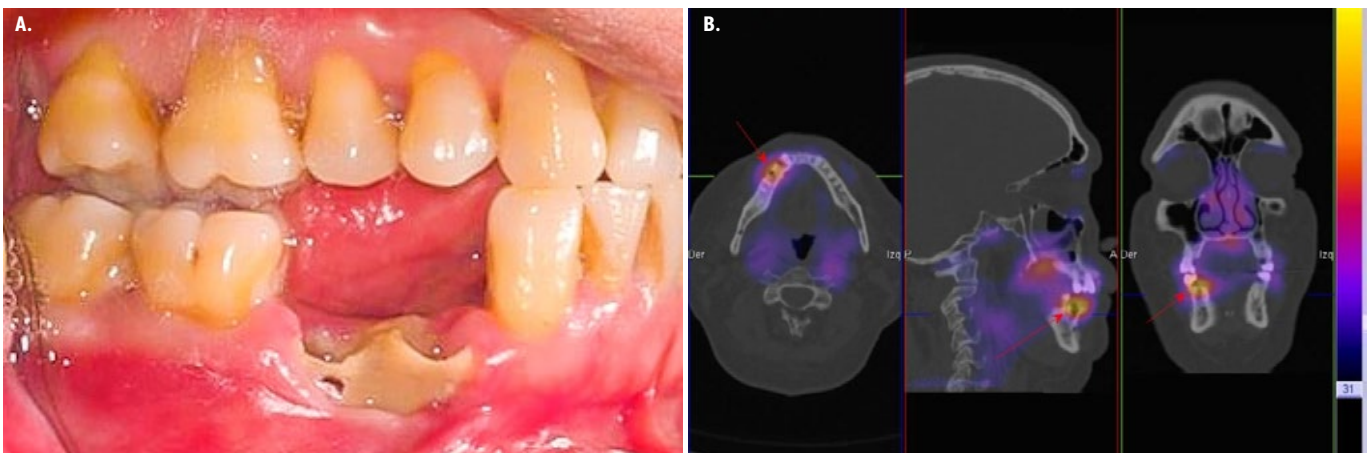
A 56-year-old man diagnosed with multiple myeloma associated with bone metastases. Hematologic treatment consisted on the administration of thalidomide, cyclophosphamide, prednisone, and zoledronic acid for ten months.

A dental extraction of the right mandibular first premolar was performed outside of our institution. A week later, the patient referred spontaneous loss of the second mandibular right premolar in addition to paresthesia in the inferior border of right mandibular body. Intraoral examination showed exposure of necrotic alveolar bone in the affected area (Figure 2A).

The orthopantomography study showed absence of bone remodeling. Furthermore, a SPECT-CT was performed where hypermetabolism was evident in the affected mandibular body (Figure 2B). The lesion was consistent to an AAOMS stage 2 MRONJ and received amoxicillin / clavulanate for three months with full recovery.



**Figure 1.** 3-D computed tomography reconstruction shows an osteolytic lesion extending from the mandibular body to the right-side ascending ramus.



**Figure 2.** A. Exposure of necrotic alveolar bone after dental extraction on premolar area. B. Spect CT shows defined extension of osteonecrosis in right mandible and demonstrated hypermetabolism evident in right-side (Red arrow).

**Case 3** – A man with multiple myeloma treated with zoledronic acid and corticosteroids.

A 74-year-old man diagnosed with multiple myeloma and multiple bone metastases was treated with thalidomide, dexamethasone, cyclophosphamide, and zoledronic acid for 19 months.

The patient reported abrupt ongoing pain in the mandibular area and trismus. Intraoral examination showed necrotic bone exposure and purulent exudate in the right molar area and swelling in the submandibular right side on extraoral examination (Figure 3A).

Orthopantomography and head and neck CT scan were performed on suspicion of a submandibular abscess. An osteolytic lesion was observed in the right molar area and a submandibular abscess (Figure 3B). Based on the clinical characteristics, the patient was classified as AAOMS stage 3.

The patient underwent abscess drainage followed by broad-spectrum antibiotic therapy with vancomycin and ertapenem for one week. After a microbial cultures *Streptococcus intermedius* was isolated and antimicrobial

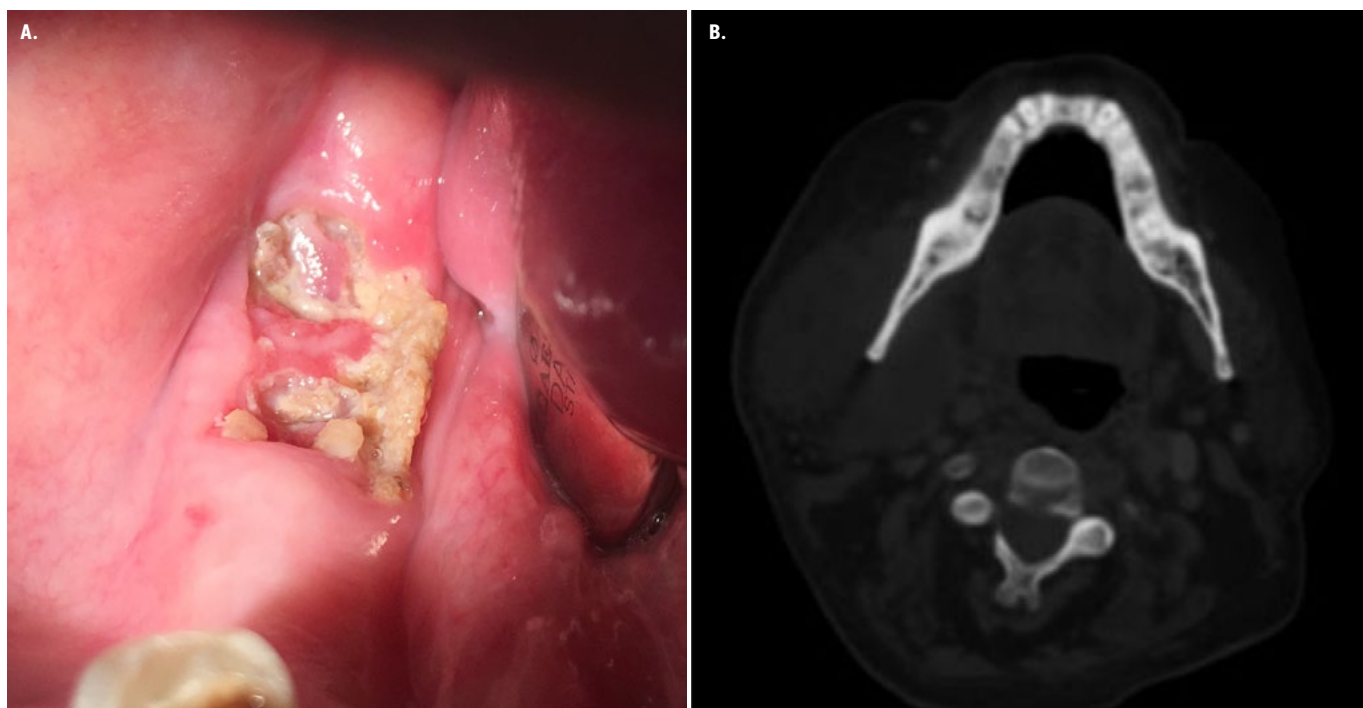
therapy was adjusted with cephalexin for one week and mouthwashes with 0.12% chlorhexidine solution for 15 days. Pain relief and full recovery was obtained.

**Case 4** – A woman with breast cancer treated with long-term zoledronic acid.

A 70-year-old woman with advanced breast cancer and multiple bone metastases was treated intermittently with zoledronic acid for four years. With a sudden onset, the patient reported pain in the right mandibular area after spontaneous loss of canine tooth. Intraoral examination showed a submental and alveolar ridge fistula with purulent exudate.

Antimicrobial treatment was initiated with clindamycin and mouthwashes with 0.12% chlorhexidine solution. Four months later, examination showed a second extraoral fistula on the right submental area with purulent discharge upon palpation. (Figure 4).

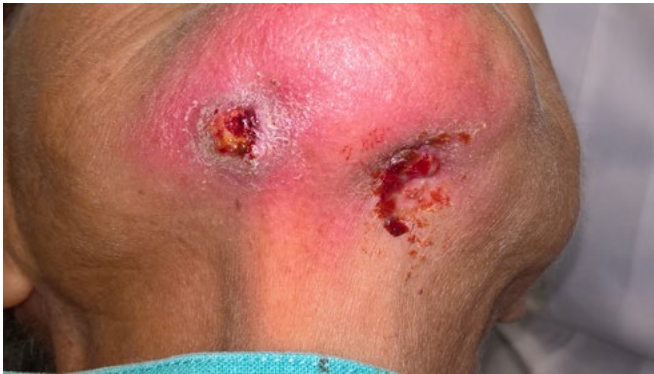Orthopantomography showed an osteolytic lesion in the lower border of the mandibular body. The patient started treatment with clindamycin for 2 weeks, mouthwashes



**Figure 3. A.** Intraoral examination showing necrotic bone exposure in right-side third molar region. **B.** Axial CT image shows the extension of submandibular space infection on the right-side.

with 0.12% chlorhexidine solution three times daily for 15 days.

After a month of treatment, she showed improvement of symptoms and the cutaneous fistula had healed without complications.



**Figure 4.** Extraoral examination demonstrated the cutaneous sinus tract in the submental region.

## DISCUSSION

In this case series we present four patients with MRONJ associated with denosumab, bisphosphonates, and bevacizumab exposure, three of the drugs most commonly associated with this complication and also three of the drugs most commonly used in daily oncologic practice in the midst of advanced disease in different tumor types.

The reason underlying the almost exclusive maxillary bone affection is still unknown. In preclinical models, it has been observed that the maxillary bones show an increased bone-remodeling activity owing to the frequent microtrauma inherent to that specific area, thus making the maxillary bones more susceptible to the inhibition of bone remodeling by antiresorptive and antiangiogenic agents. Moreover, Cheong et al. observed a direct soft tissue toxic effect with bisphosphonate exposure in a murine model favoring bacterial colonization and infections in the gingival surface (7). Additionally, VEGF is essential for the bone remodeling process as it has been shown to promote osteoclast differentiation and survival (8). Therefore, inhibition of VEGF could delay repair during wound healing and bone remodeling

and has been shown to play an important role in the development of MRONJ (9).

The incidence of MRONJ depends on the type of medication administered (antiresorptive vs. antiangiogenic agents), the indication (osteopenia/osteoporosis vs. bone metastases), and the length of exposure to the drug (6). In this manner, bisphosphonate-associated MRONJ leads the incidence of this complication with 0.7 to 6.7% of exposed patients, followed by denosumab 0.7 to 1.9%. Contrariwise, the percentage of anti-angiogenic-associated MRONJ is only 0.2% of exposed patients.(10-12) This calls for special attention to clinical symptoms in bisphosphonate-exposed patients.

It is well known that MRONJ occurs almost exclusively in patients with previous dental alterations, either inflammation (e. g. periodontitis) or secondary to dental extractions performed during concurrent treatment with any of the drugs associated with MRONJ. Furthermore, the risk of developing MRONJ after a dental extraction and concurrent exposure to an BMA is estimated to be around 2.8%, although it has been reported to be as high as 14.8% (13,14). Likewise, several other risk factors for the development of MRONJ have been identified. In a case-control study of 191 cases of MRONJ, Barasch et al. observed that the three most important risk factors associated with osteonecrosis were: 1) oral suppuration (periodontal disease), OR 7.8 [95% CI: 1.8-34.1; 2) dental extractions, OR 7.6 [95% CI: 2.4- 24.7], and 3) exposure to therapeutic radiotherapy to the mandible as part of head and neck cancer treatment, OR 24.1 [95% CI: 4.9-118.4] (15). Additionally, other authors have observed an increase in the risk of MRONJ in patients with chronic corticosteroid treatment, advanced age, and concurrent conditions such as diabetes mellitus, and tobacco consumption (16).

The AAOMS has developed clinical practice guidelines for the prevention, diagnosis, and treatment of MRONJ. With regard to prevention, several authors (17-19) recommend a thorough dental evaluation before initiating any drug associated with the development of MRONJ (Table 1). Moreover, studies by Dimopoulos, Bonacina, and Vandone et al. found a reduction of up to

50% of the incidence of MRONJ in patients exposed to antiresorptive agents when general preventive measures were applied prior to initiation, and throughout treatment. These measures included a thorough review by a certified dentist, education of the patient in oral hygiene, and the completion of surgical procedures 14 to 21 days before starting the treatment with antiresorptive agents<sup>(20-22)</sup>.

Despite the well-known preventive measures, a small percentage of patients still develop MRONJ. For these patients, urgent dental intervention is warranted in order to limit the extension of the lesion and, in selected cases, perform surgical procedures. The AAOMS treatment guidelines for MRONJ emphasize on: 1) eliminating pain, 2) controlling soft tissue infection, and 3) minimizing the progression and extent of osteonecrosis. The single most important therapeutic measure is the initiation of broad-spectrum antibiotics and thorough cleansing of the affected area with antiseptic solution followed by surgical debridement in selected cases depending on the extent of the osteonecrotic lesion<sup>(19)</sup>. Recently, non-invasive therapies have been reported to limit the spread of MRONJ. Pentoxifylline and tocopherol can be useful in non-invasive management. Furthermore, low-level laser therapy (LLLT) and teriparatide, have also gained attention as potential non-invasive therapies for MRONJ. Furthermore, once MRONJ is resolved, strengthening of oral hygiene is of utmost importance<sup>(23, 24)</sup>.

## CONCLUSIONS

MRONJ is a relatively common complication associated with the prescription of bone-modifying and antiangiogenic agents in cancer patients. In this regard, it is important to be informed concerning the prevention and treatment of this complication. It is also important to be aware of the commonly MRONJ-associated pharmacologic agents and to avoid surgical oral manipulation during concomitant treatment as outlined by the AAOMS.

In our case-series, we identified two patients with dental extractions concomitantly with antiresorptive treatment, and two patients with spontaneous loss of teeth secondary to severe periodontal disease. We were

able to identify early-onset MRONJ and to initiate rapid treatment with broad-spectrum antibiotics and antiseptic solution underlining the importance of timely referral to an experienced odontologist.

In our institution, dental health evaluation before exposure to BMAs is performed routinely. During the dental evaluation, a meticulous assessment of oral hygiene is carried out and the patient is educated regarding the risk factors for the development of MRONJ. We emphasize on avoiding dental extractions and appeal to different approaches such as endodontics for pain-relief as delineated in the AAOMS guidelines.

Some areas of opportunity are worth noting. In Latin America, there is only one retrospective analysis by Fernández et al. on MRONJ in adult patients with cancer<sup>(25)</sup>. In their study, 7 cases were described in 50 patients exposed to bisphosphonates in a period of 9 years; however, the study does not detail population risk factors, established therapeutic measures, description of patient outcomes, or detail adherence to AAOMS clinical treatment guidelines. Moreover, to date, there is no local adaptation of clinical guidelines for the prevention, diagnosis, and treatment of MRONJ in Latin America. Likewise, we also do not know if the general practice dentist is familiar with this complication or with the therapeutic measures recommended by the AAOMS. This lack of information is an area of opportunity to generate knowledge through clinical research. In this regard, our group is developing a cross-sectional study with the objective of making a situational diagnosis, to implement quality improvement initiatives to such as continuous dental education, highlighting the awareness of MRONJ to the general practice dentist.

**Authors contribution:** All authors have participated in the conceptualization, data collection, final preparation of the article and approval of the document presented.

**Funding Sources:** The authors declare no funding received

**Declaration of conflict of interest:** The authors declare no conflicts of interest with respect to this work.

## REFERENCES

- Sung H, Ferlay J, Siegel RL, Laversanne M, Soerjomataram I, Jemal A, Bray F. Global Cancer Statistics 2020: GLOBOCAN Estimates of Incidence and Mortality Worldwide for 36 Cancers in 185 Countries. *CA Cancer J Clin.* 2021 May; 71(3): 209-49. doi: 10.3322/caac.21660.
- Siegel R, Naishadham D, Jemal A. Cancer statistics, 2012. *CA Cancer J Clin.* 2012 Jan-Feb; 62(1): 10-29. doi: 10.3322/caac.20138.
- Costa L, Badia X, Chow E, Lipton A, Wardley A. Impact of skeletal complications on patients' quality of life, mobility, and functional independence. *Support Care Cancer.* 2008 Aug; 16(8): 879-89. doi: 10.1007/s00520-008-0418-0.
- Baron R, Ferrari S, Russell RG. Denosumab and bisphosphonates: different mechanisms of action and effects. *Bone.* 2011 Apr 1; 48(4): 677-92. doi: 10.1016/j.bone.2010.11.020.
- Geiger-Gritsch S, Stollenwerk B, Miksad R, Guba B, Wild C, Siebert U. Safety of bevacizumab in patients with advanced cancer: a meta-analysis of randomized controlled trials. *Oncologist.* 2010; 15(11): 1179-91. doi: 10.1634/theoncologist.2009-0155.
- Ruggiero SL, Dodson TB, Fantasia J, Goodday R, Aghaloo T, Mehrotra B, O'Ryan F. American Association of Oral and Maxillofacial Surgeons position paper on medication-related osteonecrosis of the jaw-2014 update. *J Oral Maxillofac Surg.* 2014 Oct; 72(10): 1938-56. doi: 10.1016/j.joms.2014.04.031. Epub 2014 May 5. Erratum in: *J Oral Maxillofac Surg.* 2015 Jul; 73(7): 1440. Erratum in: *J Oral Maxillofac Surg.* 2015 Sep; 73(9): 1879.
- Cheong S, Sun S, Kang B, Bezouglaia O, Elashoff D, McKenna CE, Aghaloo TL, Tetradis S. Bisphosphonate uptake in areas of tooth extraction or periapical disease. *J Oral Maxillofac Surg.* 2014 Dec; 72(12): 2461-8. doi: 10.1016/j.joms.2014.07.004.
- Aldridge SE, Lennard TW, Williams JR, Birch MA. Vascular endothelial growth factor receptors in osteoclast differentiation and function. *Biochem Biophys Res Commun.* 2005 Sep 30; 335(3): 793-8. doi: 10.1016/j.bbrc.2005.07.145.
- Estilo CL, Fournier M, Farooki A, Carlson D, Bohle G 3rd, Huryn JM. Osteonecrosis of the jaw related to bevacizumab. *J Clin Oncol.* 2008 Aug 20; 26(24): 4037-8. doi: 10.1200/JCO.2007.15.5424.
- Coleman R, Woodward E, Brown J, Cameron D, Bell R, Dodwell D, Keane M, Gil M, Davies C, Burkinshaw R, Houston SJ, Grieve RJ, Barrett-Lee PJ, Thorpe H. Safety of zoledronic acid and incidence of osteonecrosis of the jaw (ONJ) during adjuvant therapy in a randomised phase III trial (AZURE: BIG 01-04) for women with stage II/III breast cancer. *Breast Cancer Res Treat.* 2011 Jun; 127(2): 429-38. doi: 10.1007/s10549-011-1429-y.
- Guarneri V, Miles D, Robert N, Diéras V, Glaspy J, Smith I, Thomssen C, Biganzoli L, Taran T, Conte P. Bevacizumab and osteonecrosis of the jaw: incidence and association with bisphosphonate therapy in three large prospective trials in advanced breast cancer. *Breast Cancer Res Treat.* 2010 Jul; 122(1): 181-8. doi: 10.1007/s10549-010-0866-3.
- Nicolatou-Galitis O, Kouri M, Papadopoulou E, Vardas E, Galiti D, Epstein JB, Elad S, Campisi G, Tsoukalas N, Bektas-Kayhan K, Tan W, Body JJ, Migliorati C, Lalla RV; MASCC Bone Study Group. Osteonecrosis of the jaw related to non-antiresorptive medications: a systematic review. *Support Care Cancer.* 2019 Feb; 27(2): 383-94. doi: 10.1007/s00520-018-4501-x.
- Yamazaki T, Yamori M, Ishizaki T, Asai K, Goto K, Takahashi K, Nakayama T, Bessho K. Increased incidence of osteonecrosis of the jaw after tooth extraction in patients treated with bisphosphonates: a cohort study. *Int J Oral Maxillofac Surg.* 2012 Nov; 41(11): 1397-403. doi: 10.1016/j.ijom.2012.06.020.
- Hasegawa T, Hayashida S, Kondo E, Takeda Y, Miyamoto H, Kawaoka Y, Ueda N, Iwata E, Nakahara H, Kobayashi M, Soutome S, Yamada SI, Tojyo I, Kojima Y, Umeda M, Fujita S, Kurita H, Shibuya Y, Kirita T, Komori T; Japanese Study Group of Co-operative Dentistry with Medicine (JCDM). Medication-related osteonecrosis of the jaw after tooth extraction in cancer patients: a multicenter retrospective study. *Osteoporos Int.* 2019 Jan; 30(1): 231-9. doi: 10.1007/s00198-018-4746-8.
- Barasch A, Cunha-Cruz J, Curro FA, Hujuel P, Sung AH, Vena D, et al. Risk factors for osteonecrosis of the jaws: a case-control study from the CONDOR dental PBRN. *J Dent Res.* 2011 Apr; 90(4): 439-44. doi: 10.1177/0022034510397196.
- Hallmer F, Bjarnadottir O, Götrick B, Malmström P, Andersson G. Incidence of and risk factors for medication-related osteonecrosis of the jaw in women with breast cancer with bone metastasis: a population-based study. *Oral Surg Oral Med Oral Pathol Oral Radiol.* 2020 Sep; 130(3): 252-7. doi: 10.1016/j.oooo.2020.04.808.
- Khan AA, Morrison A, Hanley DA, Felsenberg D, McCauley LK, O'Ryan F, et al. Diagnosis and management of osteonecrosis of the jaw: a systematic review and international consensus. *J Bone Miner Res.* 2015 Jan; 30(1): 3-23. doi: 10.1002/jbmr.2405.
- Nicolatou-Galitis O, Schiødt M, Mendes RA, Ripamonti C, Hope S, Drudge-Coates L, Niepel D, Van den Wyngaert T. Medication-related osteonecrosis of the jaw: definition and best practice for prevention, diagnosis, and treatment. *Oral Surg Oral Med Oral Pathol Oral Radiol.* 2019 Feb; 127(2): 117-135. doi: 10.1016/j.oooo.2018.09.008.
- Beth-Tasdogan NH, Mayer B, Hussein H, Zolk O. Interventions for managing medication-related osteonecrosis of the jaw. Vol. 2017, *Cochrane Database of Systematic Reviews.* John Wiley and Sons; 2017.
- Bonacina R, Mariani U, Villa F, Villa A. Preventive strategies and clinical implications for bisphosphonate-related osteonecrosis of the jaw: a review of 282 patients. *J Can Dent Assoc.* 2011; 77: b147.
- Dimopoulos MA, Kastiris E, Bamia C, Melakopoulos I, Gika D, Roussou M, et al. Reduction of osteonecrosis of the jaw (ONJ) after implementation of preventive measures in patients with multiple myeloma treated with zoledronic acid. *Annals of Oncology.* 2009; 20(1): 117-20.

22. Vandone AM, Donadio M, Mozzati M, Ardine M, Polimeni MA, Beatrice S, et al. Impact of dental care in the prevention of bisphosphonate-associated osteonecrosis of the jaw: A single-center clinical experience. *Annals of Oncology*. 2012 Jan; 23(1): 193-200.
23. Khan AA, Morrison A, Kendler DL, Rizzoli R, Hanley DA, Felsenberg D, et al. Case-Based Review of Osteonecrosis of the Jaw (ONJ) and Application of the International Recommendations for Management From the International Task Force on ONJ. *J Clin Densitom*. 2017 Jan-Mar; 20(1): 8-24. doi: 10.1016/j.jocd.2016.09.005.
24. Fliefel R, Tröltzsch M, Kühnisch J, Ehrenfeld M, Otto S. Treatment strategies and outcomes of bisphosphonate-related osteonecrosis of the jaw (BRONJ) with characterization of patients: a systematic review. *Int J Oral Maxillofac Surg*. 2015 May; 44(5): 568-85. doi: 10.1016/j.ijom.2015.01.026.
25. Martín J, Fernández T, Flores Valdés CE, Dario E, Escobar A. Osteonecrosis de los maxilares asociada a bifosfonatos en pacientes con cáncer. *Revista de la Asociación Dental Mexicana*. 2009; 65(1): 46-9.