

# SPECIAL ARTICLE

## ZIRCONIA CROWNS FOR ORAL REHABILITATION IN PEDIATRIC DENTISTRY: A NEW AESTHETIC ALTERNATIVE

### CORONAS DE ZIRCONIA PARA LA REHABILITACIÓN ORAL EN ODONTOLOGÍA PEDIÁTRICA: UNA NUEVA ALTERNATIVA ESTÉTICA

Dessire Abal-Perleche<sup>1</sup>, Leslie Donoso-Delgado<sup>1</sup>, María Cristina Hinostrroza-Izaguirre<sup>1</sup>, María Alejandra Romero-González<sup>1</sup>, Sabina Mungi-Castañeda<sup>2</sup>, Guido Alberto Perona-Miguel de Priego<sup>3</sup>

#### ABSTRACT

For decades, stainless steel crowns have been considered the easiest and most durable restoration. However, due to the poor aesthetics they offer, these crowns are no longer acceptable to patients and/or their parents. Currently, use of crowns as a rehabilitative treatment is common and the pediatric dentist requires practical knowledge, which is why innovative aesthetic alternatives such as zirconia crowns have emerged. For this reason, the objective of this article is to offer a clinical guide to the management of zirconia crowns in the anterior and posterior regions of deciduous dentition.

**Keys words:** Crowns, mouth rehabilitation, practical guidelines

#### INTRODUCTION

Pre-formed stainless steel crowns are often considered the first option for teeth

rehabilitation in deciduous dentition. They were first used in 1950 by Humphrey (1) and due to their low cost and efficiency they have been widely used in pediatric patients (2, 3). However, in aesthetic terms, which is an essential aspect of modern practice, these crowns present disadvantages (4).

Functional prosthetic materials for aesthetic treatment have been developed to meet growing demand among patients (5, 6). In this context, new materials have been developed to replace stainless steel crowns. However, these have the disadvantage of requiring an invasive procedure that can cause inflammation, bleeding and gingival margin exposure (3).

Recently, zirconia crowns, also known as “ceramic steel” were introduced to the market for deciduous dentition use (7). Zirconia is a bioceramic that was first investigated by the German chemist Heinrich Klaproth in 1789 (8). Over the past ten years, due to the superior mechanical

**Cite as:** Abal-Perleche D, Donoso-Delgado L, Hinostrroza-Izaguirre MC, Romero-González MA, Mungi-Castañeda S, Perona-Miguel de Priego GA. Zirconia Crowns for oral rehabilitation in pediatric dentistry: A new aesthetic alternative. *Rev Cient Odontol (Lima)*. 2018; 6 (1): pp. 93-97

<sup>1</sup> POSTGRADUATE STUDENTS OF PEDIATRIC DENTISTRY AT UNIVERSIDAD CIENTÍFICA DEL SUR, LIMA, PERÚ.

<sup>2</sup> CD. ESP. MG. DOCENTE DE LA ESPECIALIDAD DE ODONTOPEDIATRÍA, UNIVERSIDAD CIENTÍFICA DEL SUR, LIMA, PERÚ.

<sup>3</sup> CD. ESP. MG. COORDINADOR DE LA MAESTRÍA EN ODONTOPEDIATRÍA, UNIVERSIDAD CIENTÍFICA DEL SUR, LIMA, PERÚ.

Dessire Abal-Perleche, Leslie Donoso-Delgado, María Cristina Hinostroza-Izaguirre, María Alejandra Romero-González, Sabina Mungi-Castañeda, Guido Alberto Perona-Miguel de Priego

properties of zirconia, the use of this ceramic as biomaterial for implants and dental crowns in dentistry has increased significantly (9). Aesthetic appearance is its main advantage. Nevertheless, one disadvantage is its thickness compared to stainless steels crowns, requiring a tooth preparation causing greater damage, and thereby increasing the risk of pulp exposure (7). In addition, manufactures recommend not only subgingival carving, but also passive fit.

With the capacity to withstand high occlusal loads in anterior and posterior regions (10,11), zirconia constitutes the strongest dental ceramic material available, achieving survival until exfoliation of the deciduous tooth. Currently, the use of crowns in deciduous teeth for rehabilitation treatment is common and the pediatric dentist requires practical knowledge (12). The purpose of this paper is to offer a clinical guide to the use of zirconia crowns in the anterior and posterior regions of deciduous dentition.

## TECHNIQUE

### Anterior teeth

1. Make incisal and vestibular cuts of approximately 1 mm depth and remove them with a round-end taper. Remove the interproximal contact points with a fissure bur. A subgingival preparation is left. (Figure 1)

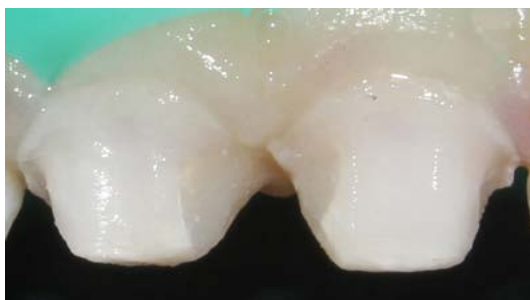

FIGURE 1. A SUBGINGIVAL PREPARATION IS LEFT.

2. Remove the supragingival shoulder with a 1 to 2 mm subgingival extension with a thin round-end taper. Bleeding usually occurs during the removal of the shoulder. It is advisable to place a hemostatic agent embedded in cotton and wait for about 5 minutes. (Figure 2)
3. Select the number of the "try-in" crown and make the final adjustment, before cementing the final crown. (Figure 3)

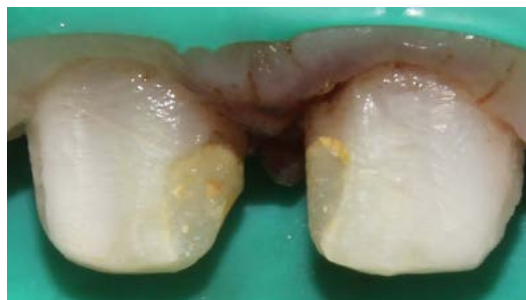


FIGURE 2. REMOVE THE SUPRAGINGIVAL SHOULDER WITH 1 TO 2 MM SUBGINGIVAL EXTENSION WITH A THIN ROUND-END TAPER.

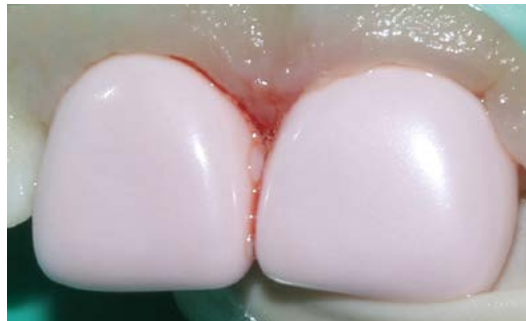

FIGURE 3. SELECT THE NUMBER OF THE "TRY-IN" CROWN

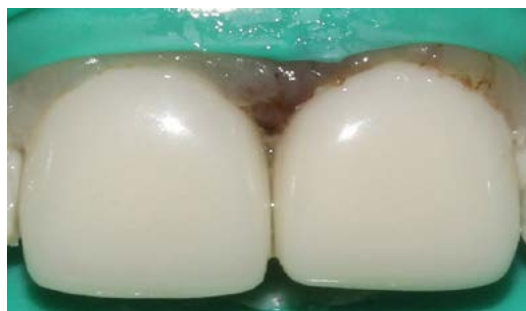

FIGURE 4. FINAL RESTORATION

4. Cement the zirconia crown with conventional glass ionomer or resinous cement. (Figure 4)

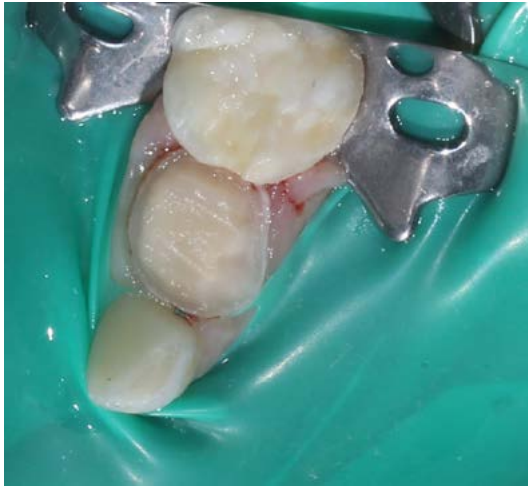

FIGURE 5. THE SUPRAGINGIVAL SHOULDER IS EXPOSED

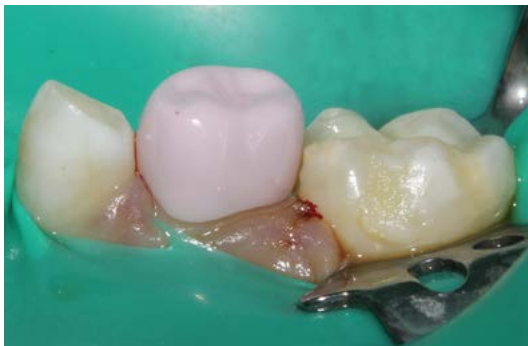

FIGURE 6. SELECT THE "TRY-IN" CROWN NUMBER

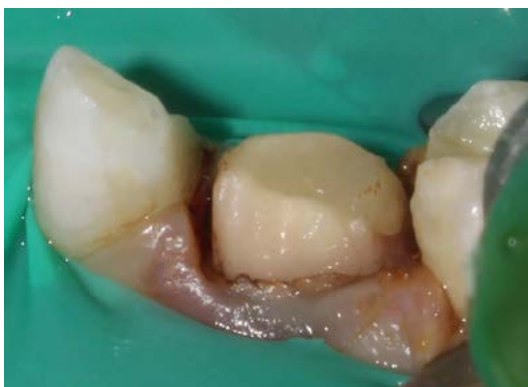

FIGURE 7. A TOOTH IS OBSERVED WITH THE SUBGINGIVAL PREPARATION

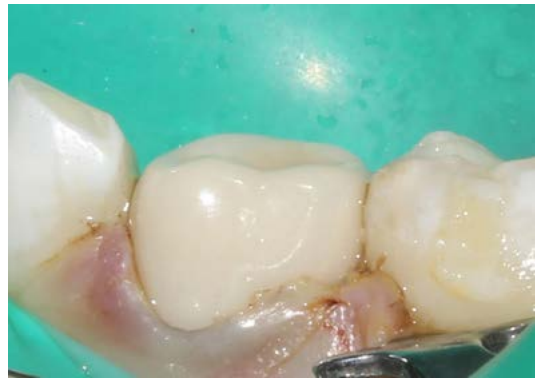


FIGURE 8. FINAL RESTORATION.

### Posterior teeth

1. Reduce the buccal and lingual cusps with a flame type coarse-grit bur. Make buccal and lingual cuts (approximately 0.5mm in depth). Remove the cuts; as well as the interproximal contact points with a round-end taper and a fissure bur, respectively. The supragingival shoulder is exposed. (Figure 5)
2. Select the "try-in" crown number and make the final adjustment, before cementing the final crown. (Figure 6)
3. Remove supragingival shoulder with a 1 to 2 mm subgingival extension with a thin round-end taper. A tooth is observed with the subgingival preparation. (Figure 7)
4. Cement the zirconia crown with conventional glass ionomer or resinous cement. (Figure 8)

## DISCUSSION

The restoration of severely decayed primary teeth has presented challenges for pediatric dentists, not only because available materials are sensitive to the technique, but also because children who require this type of rehabilitation tend to be younger and less manageable patients in terms of behavior.

Dessire Abal-Perleche, Leslie Donoso-Delgado, María Cristina Hinostroza-Izaguirre, María Alejandra Romero-González, Sabina Mungi-Castañeda, Guido Alberto Perona-Miguel de Priego

For decades, stainless steel crowns have been considered the easiest to fit and the most durable restorations. However, due to their poor aesthetics, these crowns are currently no longer acceptable to patients and/or their parents. Aesthetic alternatives such as open-faced stainless steel crowns, veneered stainless steel crowns and resin crowns have been developed over the years (3). More recently, a new type of ceramic crown based on zirconium dioxide has been developed (13).

Zirconia crowns have many advantages, such as resisting the propagation of cracks in the crown structure (14), which is a particularly important feature when primary teeth are restored in very young children, as they are prone to trauma, particularly in the case of anterior teeth. Also, they are available in different sizes, which allows for a better fit and reduces working time for the dentist. Also, they provide a highly polished surface, thereby preventing stains and plaque accumulation (15). Zirconia crowns can

be placed using a simple technique, as we have already described.

However, excessive damage to the tooth is one of the greatest disadvantages of crown preparation. Also, subgingival invasion is uncomfortable for the patient and sometimes harmful to the gingival tissue; however, in the case of pediatric patients, regeneration will be almost immediate and absolute.

In this paper, our aim is to describe sequentially the technique for making a zirconia crown, as an aesthetic alternative in the oral rehabilitation of primary dentition. To date, few articles have evaluated these crowns in deciduous dentition, and there is no clinical guide describing the sequence of procedures required. Given the growing demands of parents in terms of aesthetics, dissemination of this guide is required in order to instruct pediatric dentists in the preparation of zirconia crowns, in both anterior and posterior regions.

## REFERENCES

1. Humphrey WP. Uses of chrome steel in children's dentistry. *Dent Surv* 1950; 26: 945-9.
2. Randall RC. Preformed metal crowns for primary and permanent molar teeth: review of the literature. *Pediatr Dent* 2002; 24: 489-500.
3. MacLean JK, Champagne CE, Waggoner WF, Ditmyer MM, Casamassimo P. Clinical outcomes for primary anterior teeth treated with veneered stainless steel crowns. *Pediatr Dent* 2007; 29: 377-81.
4. Shah PV, Lee JY, Wright JT. Clinical success and parental satisfaction with anterior veneered primary stainless steel crowns. *Pediatr Dent* 2004; 26: 391-5.
5. Zimmerman JA, Feigal RJ, Till MJ, Hodges JS. Parental attitudes on restorative materials as factors influencing current use in pediatric dentistry. *Pediatr Dent* 2009; 31: 63-70.

6. Pani SC, Saffan AA, Al Hobail S, Bin Salem F, Al Furaih A, Al Tamimi M. Esthetic Concerns and Acceptability of Treatment Modalities in Primary Teeth: A Comparison between Children and Their Parents. *International Journal of Dentistry. Int J Dent.* 2016;2016:3163904. doi: 10.1155/2016/3163904. Epub 2016 Jun 29.
7. Choil JW, Bae IH, Noh TH, Ju SW, Lee TK, Ahn JS, et al. Wear of primary teeth caused by opposed all-ceramic or stainless steel crowns. *J Adv Prosthodont.* 2016; 8: 43-52.
8. Pilathadka S1, Vahalová D, Vosáhlo T. The Zirconia: a new dental ceramic material. An overview. *Prague Med Rep.* 2007; 108 (1):5-12
9. Gautam C, Joyner J, Gautam A, Rao J, Vajtai R. Zirconia based dental ceramics: structure, mechanical properties, biocompatibility and applications. 2016;45(48):19194-215.
10. Schley JS, Heussen N, Reich S, Fischer J, Haselhuhn K, Wolfart S. Survival probability of zirconia-based fixed dental prostheses up to 5 yr: a systematic review of the literature. *Eur J Oral Sci.* 2010; 118: 443–50.
11. Komine F, Taguchi K, Fushiki R, Kamio S, Iwasaki T, Matsumura H. In vitro comparison of fracture load of implant-supported, zirconia-based, porcelain- and composite-layered restorations after artificial aging. *Dent Mater J.* 2014; 33: 607–13.
12. Dolan TA, Gilbert GH, Duncan RP, Foerster U. Risk indicators of edentulism, partial tooth loss and prosthetic status among black and white middle-aged and older adults. *Community Dent Oral Epidemiol.* 2001; 29(5):329-40.
13. Karaca B, Ozbay G, Kargul, B: Primary zirconia crown restorations for children with early childhood caries. *Acta Stomatol croat;* 2013; 47(1): 64-71.
14. Larsson C. Zirconium dioxide based dental restorations. Studies on clinical performance and fracture behaviour. *Swed Dent J Suppl.* 2011; (213):9-84.
15. Ashima G, Sarabjot KB, Gauba K, Mittal HC. Zirconia crowns for rehabilitation of decayed primary incisors: an esthetic alternative. *J Clin Pediatr Dent.* 2014;39(1):18-22.

CORRESPONDENCIA: [mar\\_crist22@hotmail.com](mailto:mar_crist22@hotmail.com), [leslie.donos08@gmail.com](mailto:leslie.donos08@gmail.com)

RECIBIDO: 22/03/2018

ACEPTADO: 16/05/2018